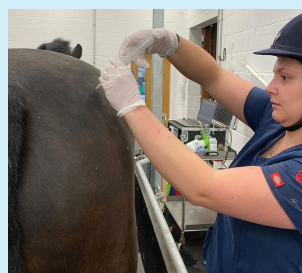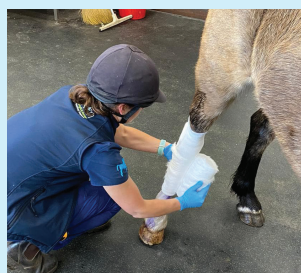


# Wright & Morten Equine Newsletter



[www.wmvets.co.uk](http://www.wmvets.co.uk)

June 2021



## Vet Nursing Awareness Month

The purpose of VNAM is to spread the word to the veterinary profession and pet owners, about the importance of the role of the veterinary nurse in practice, and the provision of responsible pet care to the general public.

Here at W&M Equine clinic we have a fantastic team who work tirelessly assisting vets, caring for your horses/ donkeys whilst here at the clinic, and assisting where needed out on farm visits. Whilst they are extremely busy they spend time getting to know every patient and ensure that there every need is catered for. Here are some examples of the work they do. Huge shout out to Lou P, Lou S, Kayleigh, Gemma, Hannah, Eadie, Daga and Caitlin...



## We are delighted to welcome Hannah Phillips to Wright and Morten, to complete our vet team...

Hannah graduated from the university of Liverpool in 2019 and spent the first 2 years working at a large animal and equine vets in Bolton. She has a keen interest in equine medicine, with her main interests being neurology and cardiology.

Hannah has two miniature daschunds, Pumpkin and Pepper, who you might bump into around the peaks or in the lakes. Despite their little legs they love climbing hills, and will soon be attempting to climb the Wainwrights.



## Congratulations Nic

Nic Harries has recently been awarded Recognised Advanced Practitioner status in Equine Dentistry by the Royal College of Veterinary Surgeons. This is an official recognition of a veterinary surgeon's particular knowledge, skills and experience in a designated field of veterinary practice. It reflects current knowledge and understanding in the area of expertise, advanced professional skills and commitment to the continuing improvement of personal and professional practice.

At Wright and Morten we perform routine equine dentistry, as well as more complex cases including extractions and fillings.

Nic is also a RCVS recognised practitioner in Equine Surgery- Orthopaedics.



# Osteoarthritis in the horse

## Anatomy of a joint

A joint is where 2 or more bones meet. At the end of each bone is cartilage. Chondrocytes are the main cell which produces the components of cartilage. In a normal joint cartilage is constantly degraded and replaced at a balanced rate. The area of bone directly under the cartilage is referred to as the subcondral bone.

Each joint is then lined by a joint capsule. The inner aspect of this joint capsule is the synovial membrane which has contact with the synovial fluid that sits within a joint. The synovial membrane acts as a barrier controlling components into and out of the synovial fluid. Synovial fluid is responsible for lubricating the joint to allow frictionless movement.

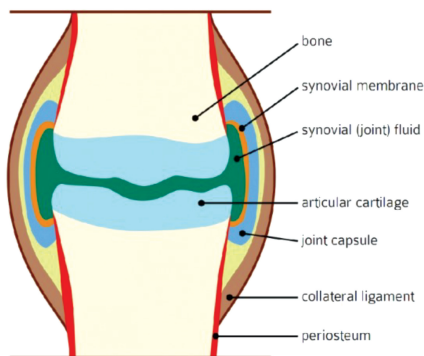


Image credit: www.horsejournals.com

## What is osteoarthritis?

Osteoarthritis (OA) is one of the most common cause of lameness in our patients. Osteoarthritis is a degenerative condition which is characterised by damage to and loss of the cartilage layer in the joint, leading to pain and inflammation. The primary role of cartilage is to protect the ends of bones within a joint to allow frictionless movement and absorb shock, which in turn protects the sub-chondral bone underneath.

When we consider why OA happens in a joint we talk about joint trauma. This is not trauma in the classic blunt trauma sense but refers more to the overloading of a joint. A certain amount of joint loading is needed for joint lubrication and the production of proteoglycans, which are an important component of cartilage. However if a joint is loaded above its ideal threshold the joint responds by trying to remodel, resulting in reduced shock absorbing ability of the subcondral bone and more pressure onto the cartilage layer which begins to breakdown.

Trauma to a joint also results in the synovial membrane becoming more permeable, allowing more fluid to move into a joint resulting in effusion and pain. Chronic inflammation can also result in thickening of the synovial membrane and joint capsule creating a stiff joint with reduced shock absorption.

Although we commonly assume OA is a condition of wear and tear in the older horse, the

development of OA can occur for a wider variety of reasons in all ages of horses. Less commonly, OA can occur secondary to conditions such as an infection in the joint, fractures which communicate with the joint and developmental conditions such as osteochondrosis dissecans (OCD). Conformation, genetics, weight and exercise can all play a part in the development of OA.

## How is it diagnosed?

Diagnosing OA is often multimodal. This is because we first need to localise the source of pain using local anaesthetic blocks- these may initially be regional blocks to regionalise the cause of lameness e.g. foot, followed by more specific joint blocks e.g. coffin joint. Sometimes we may be able to palpate swelling of certain joints which can give us a clue that this joint may be painful- swelling of a joint indicates increased joint fluid due to inflammation. Once we have located the source of pain we will image the area to determine if there is any evidence of joint pathology. On x-rays we might see:

- New bone formation at the joint margin (bone spur) or at attachment site of soft tissue structures
- Narrowing of joint spaces
- Change in the sub chondral bone appearance (sub chondral bone sclerosis)

However, we must bear in mind studies have in shown certain joints (namely the small hock joints) the relationship between the severity of signs seen on x-rays is poorly correlated to the degree of pain shown by the horse so some horses may have advanced OA signs on x-rays but have no associated pain and visa versa- this is why we must start by localising the source of pain first rather than just imaging the horse. It is also important to bear in mind that x-rays only allows us to visualise bone. Often there are multiple soft tissue structures associated with a joint and these may need imaging with ultrasonography or in some cases with MRI.

Often the damaged cartilage layer is not the most painful part for the horse- the subsequent inflammation within the joint causes physical swelling of the joint, thickening of the joint capsule (capsulitis) and inflammation of the lining of the joint (synovitis).

## How is OA treated?

We are lucky to have a variety of types of medication at our disposal and the choice will depend on type and severity of OA, the intended use, age of the horse and finances available. Some of the treatment options include:

**1. Non-steroidal anti-inflammatory drugs** (NSAIDs) such as 'bute' or 'Danilon' – these are oral anti-inflammatory medications, similar to us using ibuprofen. Although they have their place and are still widely used, often in combination with other treatments, they are banned in competing horses and can have side effects when used long term or at high

doses.

**2. Joint injections** - injecting treatment directly into the joint is a good way of providing targeted treatment to the problem area. This must be done under sterile conditions and we recommend bringing horses to the clinic for these treatments to reduce the risk of complications and increase safety. We have a few options of specific joint treatments:

- Corticosteroids are strong anti-inflammatory drugs which act to significantly reduce pain and inflammation within a joint. They often act as a fire blanket treatment as they have a quick onset but also can wear off quickly and may need repeating at regular intervals. Certain corticosteroids can deteriorate the cartilage layer further so if regular treatments are needed we may consider alternatives.
- Polyacrylamide hydrogel (Arthramid) is a collagen based product which once injected into the joint incorporates itself into the joint lining and helps improve the elasticity of the joint capsule and improve the quality of joint fluid. This is particularly useful as a long term for coffin and fetlock OA.
- Hyaluronic acid is a treatment specifically aimed at improving the quality and quantity of joint fluid. This may be injected at the same time as a corticosteroid.
- Ethanol- this is limited to only certain low motion joints eg small hocks joints and causes a non-reversible chemical fusion of the joint- this kills the nerve endings and can be very effective in certain cases.

**3. Joint supplements** can help slow the progression of OA and ones containing Boswellia have additional anti-inflammatory effects. We can provide a specific joint supplement information sheet to help you pick a joint supplement that is best for your horse.

**4. Systemic treatments** for OA include drugs such as 'Cartrophen' (pentosan polysulphate) and 'Tildren' (Tilduronic acid) and are whole body treatments which aim to slow the degenerative changes in multiple joints. Tildren is given via an intravenous infusion, 2 treatments 6 weeks apart. Cartrophen is given via an intramuscular injection, 4 treatments at weekly intervals.

Unfortunately OA cannot be cured but we can aim to suppress the symptoms to allow the horse to return to soundness and continue its career whether that is as a competition horse, a happy hacker or a companion. As well as the treatments described above, an appropriate exercise programme is important to encourage the horse to work correctly and develop core strength which reduces excessive overloading of certain joints. Regular physiotherapy can help maintain range of movement and prevent/ address any muscle tightness as good farriery is also very important.

## EQUINE CLINIC

Somerford Park, Holmes Chapel Road, Somerford, Cheshire, CW12 4SW Tel: 01260 280800 Email: somerford@wmvets.co.uk

Like us on Facebook for up-to-date news and the latest events! Search 'Wright & Morten Equine Clinic'

