

valere referrals



Newsletter

Hello and welcome to Vale Referrals' autumn newsletter 2018. After a hot and busy summer we are now cooling down into a productive autumn and winter.

The Vale Referrals team would like to thank you all for your continued support over the last year and we are excited to continue to offer you and your clients the care and expertise of our fantastic team!



We are delighted to announce that Sian Blakey is now with us full time at Vale. Sian is part of our referral medicine team and has a particular interest in feline medicine and geriatrics.

We have expanded our surgical team and welcome Michal Vlasin DVM PhD MRCVS. Michal has joined us from Cambridge University and will be working alongside Richard Artingstall performing soft tissue and orthopaedic surgeries. Michal has published many papers and holds post graduate qualifications in Small Animal Surgery, Haematology, Microsurgery and Medical Education.



Another new team member who joined us at the start of August is Laura Dickenson, our referrals manager. Laura will soon be out on the road visiting local practices and liaising with you all to see how we can improve and develop our services. If you have any queries or questions relating to referrals you can contact Laura to discuss these at anytime.

Building our future! Vale is constantly growing and evolving and we need to expand our premises to accommodate this. We are starting the build by improving our parking facilities before beginning work on the interior. Work is estimated to start Winter 2018 and we will send out more information to you all soon. We have a project team on-site who will ensure minimal disruption is made to clients and patients alike.



We are excited to announce that we are extending our Oncology service into Wales by offering a weekly oncology clinic at Alpha Vets in Newport. We hope this will be more accessible for your clients and offer greater availability of appointments. If you have an oncology case you wish to discuss with us then please contact us on 01453 547934.



Haematuria - spotting the signs

Written by Stefano Zago DVM (Hons) MSc (Clin Onc) MRCVS



Teddy is a 5 year old neutered male greyhound who recently presented to the medicine team following a few episodes of haematuria first noted last April. He was otherwise well, with good appetite and exercise tolerance, drinking normally and no other clinical signs. Clinical examination was completely unremarkable.

Initial investigations included haematology, biochemistry, coagulation profile, Angiostrongylus SNAP test and urinalysis on a cystocentesis sample.

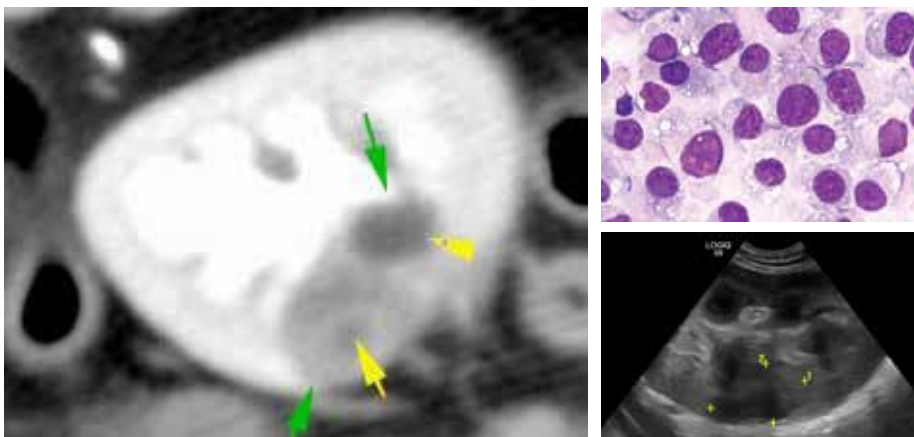
Results were normal or negative except for severe haematuria with negative culture.

Diagnostic imaging started with an abdominal ultrasound to evaluate the urinary tract. Bladder and right kidney were unremarkable but the left kidney showed a small ill-defined lesion at the cortico-medullary junction. The lesion was sampled via fine needle aspirate biopsy and results were consistent with a neoplastic population of uncertain origin. In order to better define the

renal lesion and fully stage the patient, a CT scan of chest and abdomen was performed. The CT identified a 2cm lesion with no additional metastatic lesions. Teddy underwent nephrectomy and recovered uneventfully. The initial histology report was suggestive of a histiocytic sarcoma and further immunohistochemistry staining confirmed the diagnosis. Histiocytic sarcoma is part of a group of histiocytic diseases that includes malignant (localised and disseminated sarcoma),

benign neoplasia (histiocytoma) and inflammatory and reactive diseases (cutaneous and systemic histiocytosis). Disseminated histiocytic sarcoma carries a very poor prognosis but the localised form may show slower progression with median survival time of 1-1.5 years following surgery and chemotherapy; eventually though most dogs will succumb to metastatic disease.

Teddy recently started a chemotherapy protocol that includes doxorubicin and lomustine and will be monitored over the following months.



Left: CT Image Top: Cytology Bottom: Ultrasound image

The medicine team at Vale Referrals likes endoscopy... a lot.



Written by Sian Blakey BVetMed CertAVP (SAM) MRCVS

We offer a range of endoscopic services to aid with diagnostic investigation and treatment; often avoiding more invasive surgical procedures. This includes anything from gastroscopy and cystoscopy, to rhinoscopy and bronchoscopy. Cases are typically managed as day patients and we are more than happy to discuss next day referral if needed. A challenging foreign body removal is right up our street!

Vaginal foreign body: Lily, 8 year old Retriever

When 8 year old Lily presented with a 3 month history of an intermittent vulval discharge, we were concerned for what we might find.

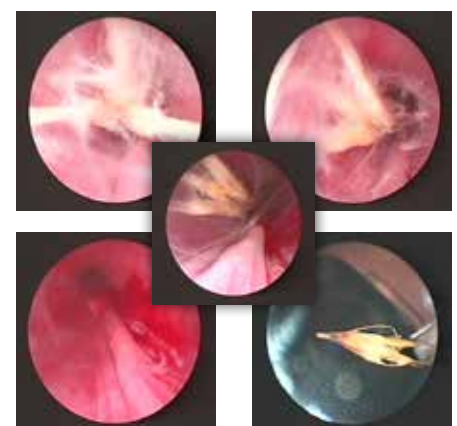
Her owner reported her to constantly lick her vulva (often stopping on a walk or whilst eating to do so) and there had been no change to her pattern of urination. She had been spayed 4 years previously and her referring vet had already measured her anti-mullerian hormone, in case of an ovarian remnant. Ultrasound examination of the abdomen and digital examination of the vagina was unremarkable. Urinalysis was performed

on a sample collected by cystocentesis, which showed no evidence to support cystitis.

After discussion with her owner, cystoscopy was performed to assess the vagina and urethra in more detail. And we had a small surprise....

It turned out Lily had been harbouring a grass seed in her vagina!

With careful assessment of the foreign body and endoscopic forceps, we were able to remove the grass seed and Lily's (slightly embarrassing) troubles were resolved!



All: Cystoscopy found a grass seed!

Bronchial foreign body: Monty, 2 year old Spaniel

When the normally bouncy Monty began coughing and showing less interest in playing with his ball, we were very keen to find out what was bothering him.

It turns out his coughing had started after a particularly exciting walk in some cornfields 3 weeks earlier and although he had shown some initial improvement with meloxicam, his cough persisted. After discussion with his owner, Monty was admitted for further investigation - although for him, this mostly meant a

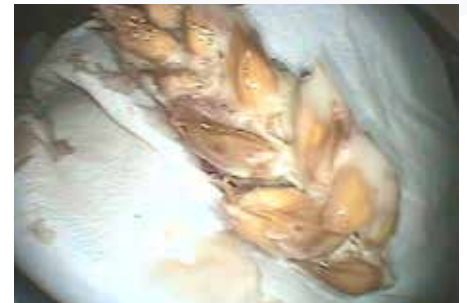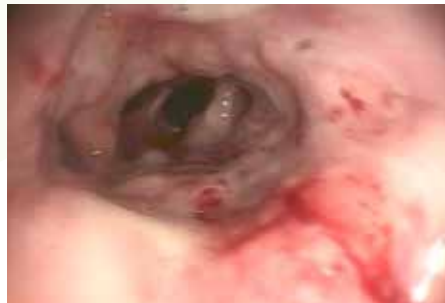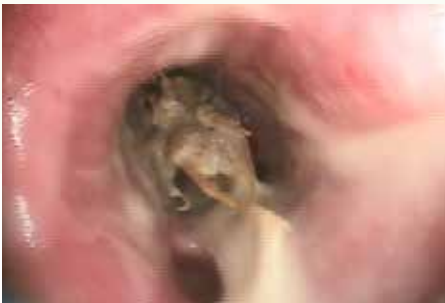chance to be fussed by all the nurses.

Bronchoscopy revealed that Monty had come back from the walk with more than just his ball; with an ear of corn lodged in his right main stem bronchus.

Airway foreign bodies are common in late summer or autumn and their removal can be challenging - particularly with corn heads or grass seeds where it is all too easy to grasp the seeds which will invariably break off the main stalk. They often require time and patience

to inspect the foreign body, as purulent material will have accumulated around it, impairing visualisation.

Monty's unwelcome addition was successfully removed intact using grasping forceps and Monty was discharged that afternoon.



Above: Corn lodged in right main stem bronchus

Oesophageal foreign body: Megan, 1 year old Labrador

Megan presented as a Sunday afternoon emergency following a fishing trip with her Dad. Despite being an experienced fisher-dog, she had got a little carried away and managed to swallow one his fish hooks.

She had presented to her referring vet with unproductive retching and thoracic radiographs identified the hook to be lodged within the oesophagus; which was agreed to be less than ideal.

All oesophageal foreign bodies should be treated as an emergency and require immediate removal. A delay can increase

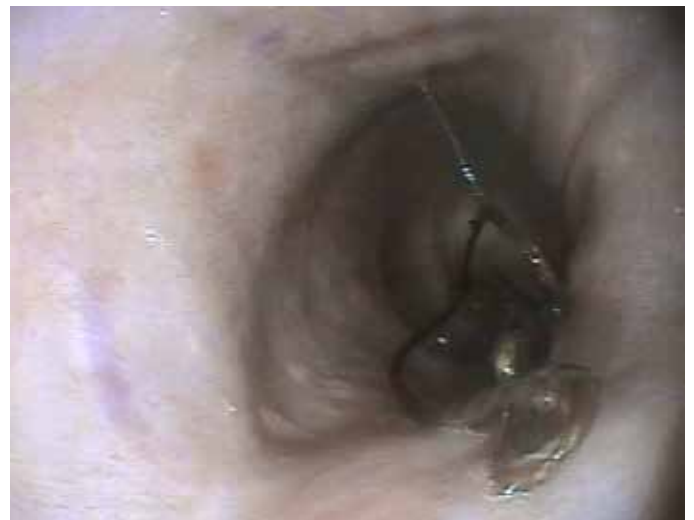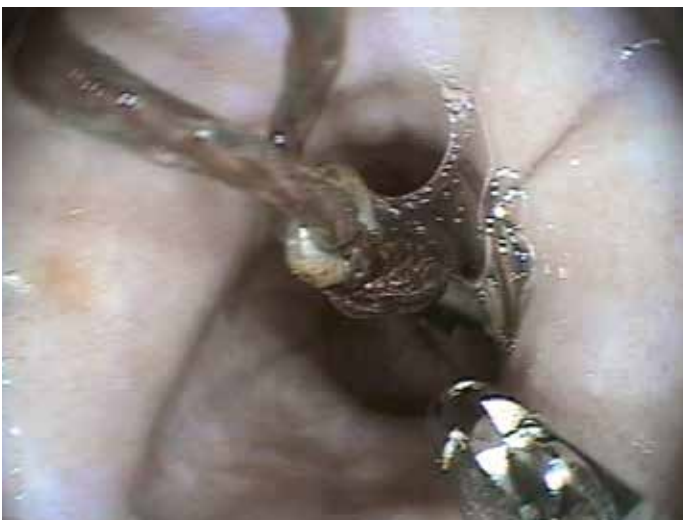the chance of pressure necrosis and subsequent perforation, or stricture formation following removal.

With a 'high risk' oesophageal foreign body such as this, we will co-ordinate with our surgical team in the event of needing an emergency thoracotomy. Occasionally, we may not be able to remove a foreign body orally and these are pushed into the stomach to then be removed by gastrotomy.

In Megan's case, a variety of techniques are used to safely dislodge and remove the fishing hook, taking care to avoid

tearing of the oesophageal wall or additional trauma to the wall as it is carefully supported up and out of the mouth.

Subsequent assessment of the oesophagus following its removal showed only minor, focal damage to the wall. Megan was monitored in the hospital overnight to ensure she was eating without complication and was discharged the next day, having made a full recovery.



Left & Right: Removal of a fishing hook via gastrotomy

Easy Referral

To help make sending a referral as quick and easy for you as possible, we have an online referral form which also allows you to upload patient history and diagnostic work.

Once we have received your referral with all the relevant history we will contact your client and arrange their appointment. CT outpatient requests can also be easily sent to us online.

Just head to <https://www.valereferrals.co.uk/CT-request/>

Cases referred to Vale since July 2018

Ophthalmology	268
Medicine	952
Dermatology	42
Cardiology	305
Surgery	328
Total Cases	1895

How do we rate?

We strive to offer your client the best service and care and understand that your clients experience contributes to your reason for choosing us as your referral centre. Vale Referrals send out a client questionnaire following your clients visit and our aim will be to provide you all with a biannual report on the cases we have seen from you. This will include which disciplines you have referred to, case outcome and how your client found their experience. We will also highlight any feedback where we have had to review and improve our service, to show our passion and dedication for developing and improving our services to you and your client.

What some clients have said about us.

Client from Usk Vets says:

"I came from the visit knowing my pets best interests were priority and he was loved whilst there"

Client from Brambles says:

"I have no problems with the service received, more than excellent"

Some feedback we received and are actioning to improve was ...

Client from Bromyard Vets says:

"When traveling from a distance to your clinic, and waiting for most of the day the availability to get WiFi and work while waiting would be invaluable. The farm shop I was directed to did not have WIFI and I ended up driving around to find somewhere to work from"

Although this client scored us 10/10 on:

- Overall communication with Vale Referrals
- The efficiency, care and attention given by our clinician during the consultation.
- The explanation of their pet's condition, diagnosis and potential treatment options.
- The quality of the inpatient care and our communication with your client.
- The explanation and care given at discharge and during the aftercare process
- The quality of the inpatient care and our communication.
- The explanation and care given at discharge and during the aftercare process
- The overall quality and service

It is still important to acknowledge that their experience could still be improved. In response to this we are creating a list of local cafes and places of interest locally that offer wifi and somewhere to eat. We have also requested some discount coffee vouchers in return for recommendations. These are scheduled to be included in our welcome packs.

Out of hours service

For out of hour emergency advice or for emergency referral please call

Telephone: 01453 547934 📞