

## Aspergillosis In Falconry Birds

Aspergillosis is the most commonly identified fungal infection in captive birds. A number of falconry birds are particularly susceptible – Gyr falcons, Goshawks, Golden eagles, Juvenile red tailed buzzards and Snowy Owls are certainly over represented in clinical cases.

Aspergillosis occurs due to colonisation of the respiratory tract with fungal hyphae of the genus *Aspergillus*. The fungal hyphae are small helping them to colonise the warm/moist surfaces of the respiratory tract. Infection is typically *Aspergillus fumigatus* but *A. terreus*, *A. flavus*, *A. niger* and *A. nidulans* are reported infrequently. *A. fumigatus* spores are ubiquitous (found everywhere), and clinical infection results from either exposure to overwhelming quantities or immune suppression (typically caused by stress or disease).

Aspergillosis is able to grow at a wide range of temperatures and is resistant to temperatures up to 70C. In optimal conditions it can grow quickly – colonies are initially white in colour but become grey/green as they age.

Aspergillosis is not a contagious disease, but can occur as a flock/collection problem where husbandry conditions predispose multiple birds to disease. Acute (sudden onset) and chronic (slowly developing) disease can both occur. Acute disease is most commonly associated with exposure to overwhelmingly large numbers of spores.

### Environmental predispositions:

Overwhelmingly large numbers of spores can be found in decomposing organic material, in particular hay, compost and wood. Poor ventilation and inadequate sanitation increase the risk of infection. Sources of aspergillosis spores include the aviary substrate, (woodchip/bark), nesting materials (hay, straw, wood chip), compost heaps, surrounding plants (ie pampas grass), building materials (rotting aviary wood) and damp/mould in the house.

### Stress/Medical predispositions:

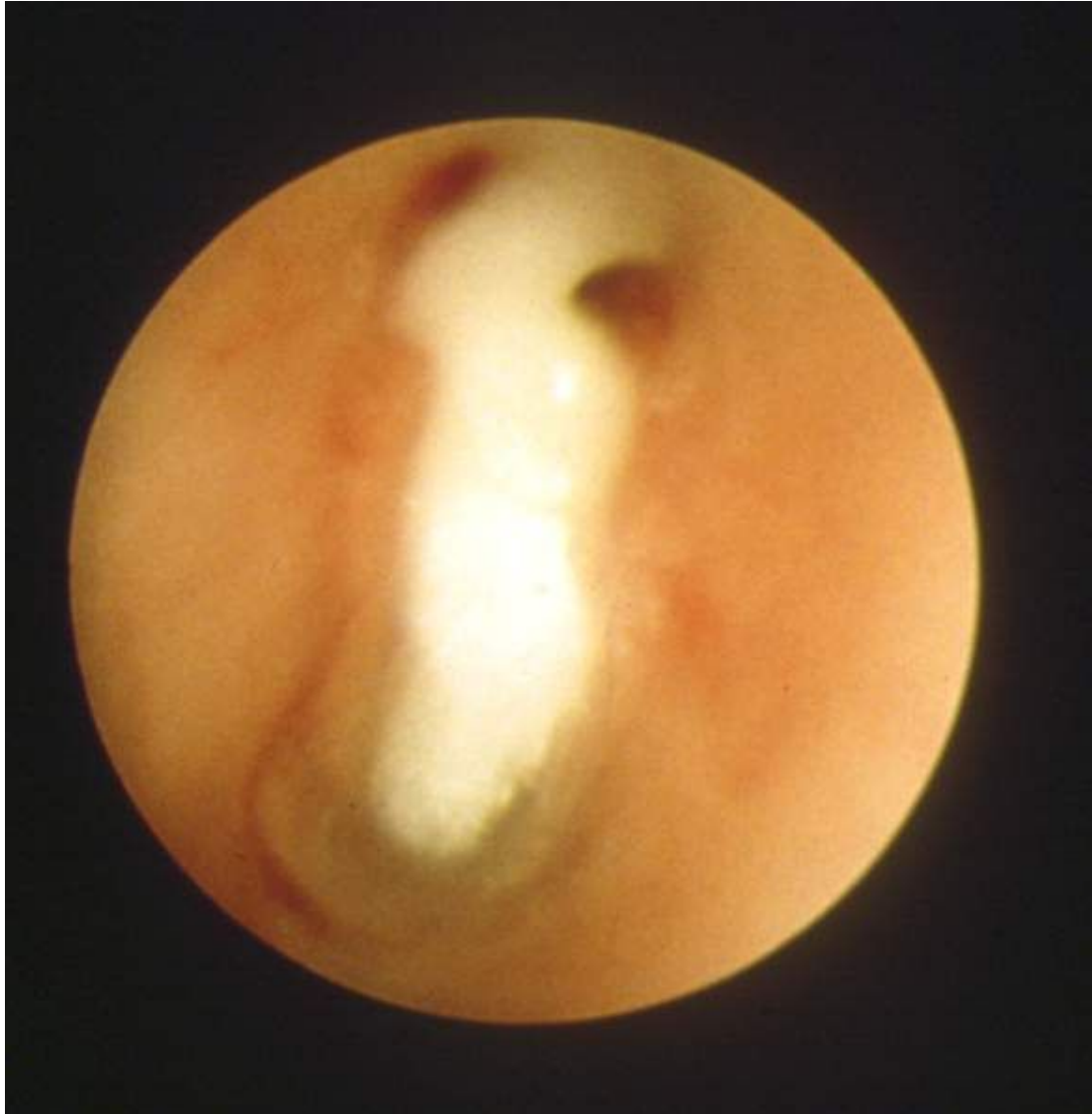Mixing of groups of birds, isolation of social animals or the onset of training are all possible stressors that can trigger infection due to immunosuppression. If a bird is immunosuppressed it can no longer cope with the normal environmental level of spores which would otherwise not be a problem. Administration of certain medications, overcrowding, shipping, quarantine, inadequate nutrition/excessive weight loss, starvation, thermal discomfort, toxicosis (e.g., heavy metals - lead), traumatic injuries, and reproductive activity. For falconers involved in rehabilitation – bringing wild injured/sick falcons into captivity is a well-known risk factor for developing aspergillosis.

### Forms of disease:

Aspergillosis typically causes disease in one or more anatomical areas of the respiratory tract: the syrinx, lung and air sacs are the most typically colonised sites. The respiratory tract of birds is far more susceptible than mammals to colonisation with aspergillosis.

**Syrinx (avian voice box – found at base of trachea):** When a granuloma grows at the syrinx birds present with a change or loss of voice, progressing to difficulty breathing.

Diagnosis is by tracheoscopy (thin camera passed down the trachea) identifying the fungal granuloma. A sample of the fungus will be collected to confirm the diagnosis. Sometimes fungal growths at the syrinx can be surgically removed – otherwise long-term medical management is required.

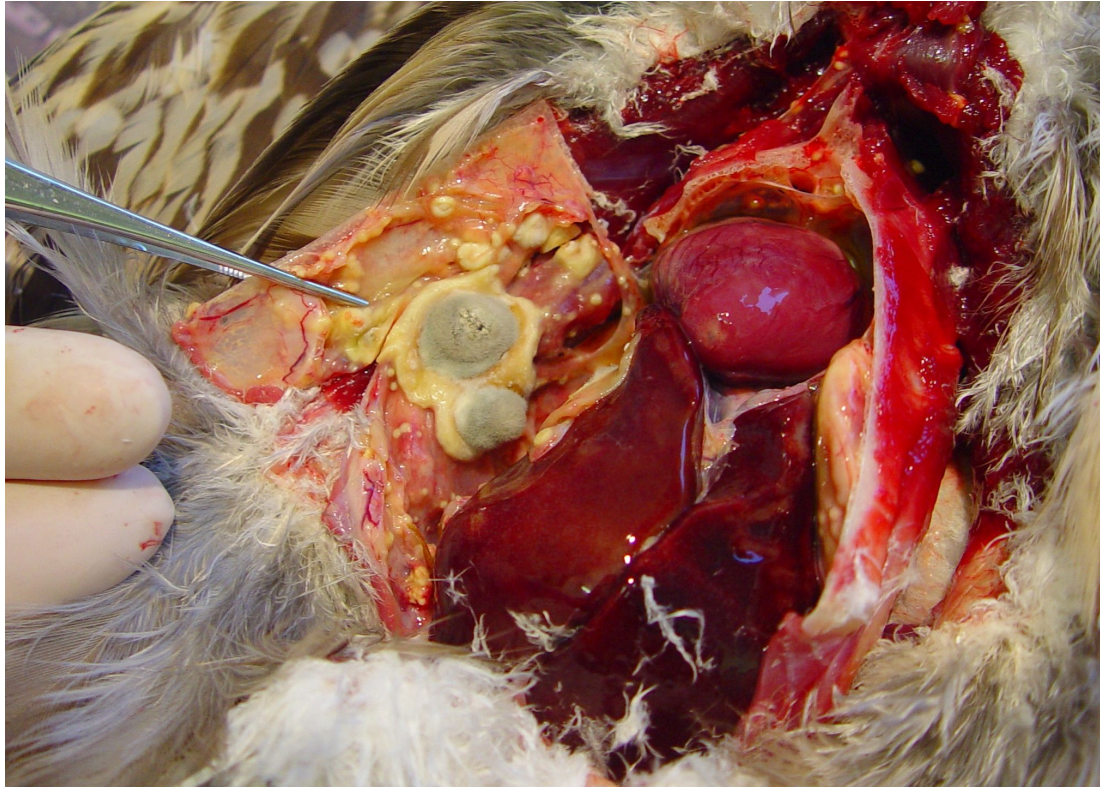


**Tracheoscopy showing almost complete syrinx obstruction by an aspergilloma**

**Lung:** Lung based disease is often the most severe. Birds present with severe breathing difficulties. X-rays, CT scanning can identify suspicious regions and confirmation is achieved with endoscopy. Prognosis when severe lung disease is present is very poor and birds often require euthanasia or otherwise die of respiratory failure.

**Air sacs:** Birds have a unique respiratory system – with a series of air-sacs helping to draw air across the lungs. Due to the large respiratory reserve in birds air-sac aspergillosis often has to be quite severe before respiratory signs are easily seen. The air sacs are not involved in gas exchange so symptoms relate to hepatic damage secondary to aflatoxin production. This frequently confuses falconers who associate aspergillosis with respiratory signs only. Clinical signs can be non-specific. Typical symptoms include poor response to training, lethargy,

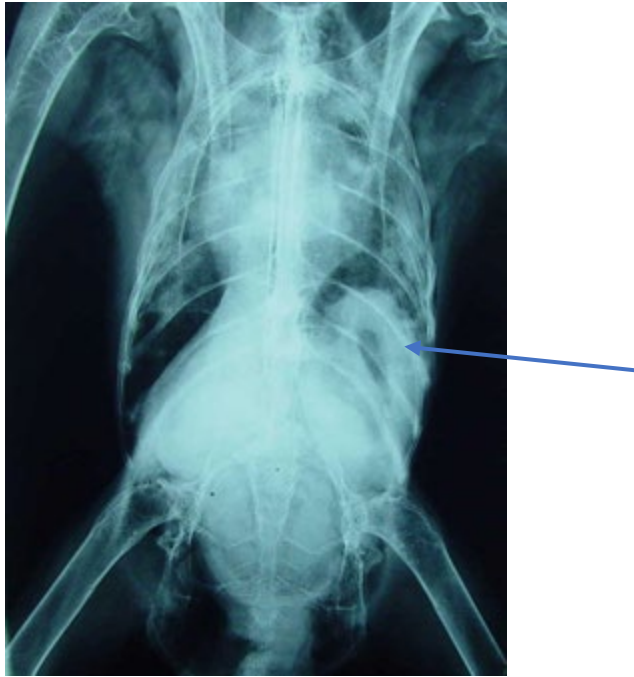
weight loss despite good appetite, increased biliverdin (green discoloration) in the faeces, vomiting and food flicking. Suspicion of disease is made based on CT scans or radiographs and confirmed by endoscopy and biopsy. Treatment involves extensive medical therapy, and can be supported by spraying the lesion at endoscopy with a suitable anti-fungal solution. Depending on the site, endoscopic removal after a week of medical therapy may be useful.



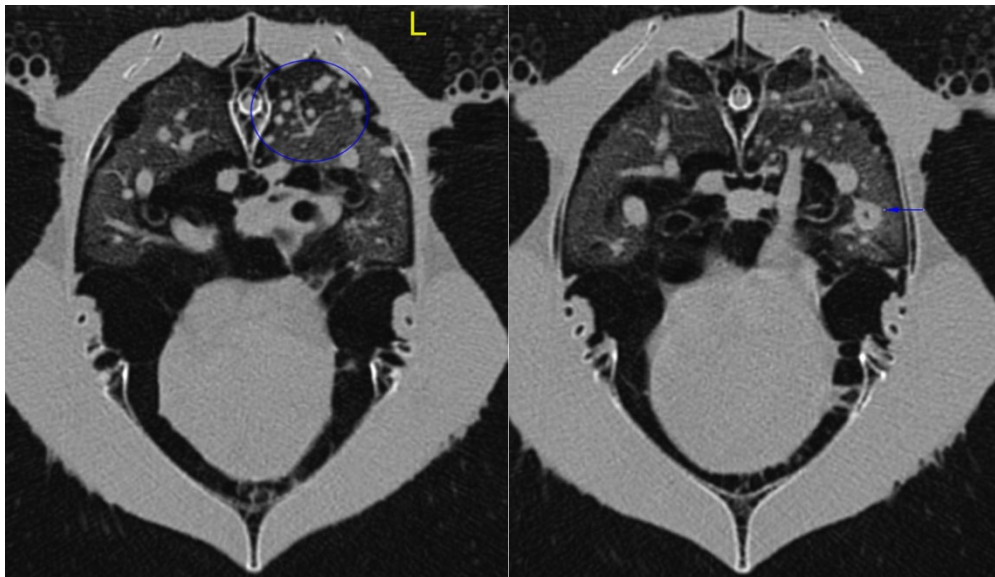
**Two large, and multiple small aspergillomas on the air sac wall at post-mortem**

### **Diagnosing aspergillosis:**

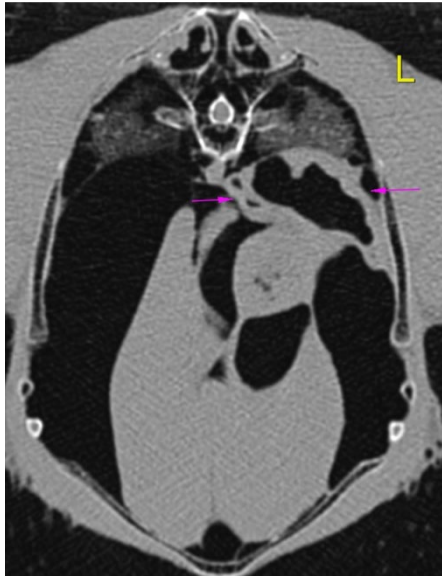
Early diagnosis improves success of aspergillosis treatment. A number of different tests are available to help diagnose aspergillosis in birds. The main way of confirming aspergillosis infection is endoscopic biopsy and analysis of the tissue. However xrays and more recently CT scans are very useful in identifying abnormal areas of the respiratory tract to be biopsied with endoscopic guidance. Blood tests will often show inflammatory responses suggestive of infections such as aspergillosis. Blood tests will also be used to monitor possible organ damage that can occur due to infection – and sometimes as a side effect of treatment.



Arrow marking an air-sac lesion aspergillosis lesion in this radiograph.



CT cross section showing lung aspergillosis lesions in a golden eagle. Marked with blue circle and arrow.



**Severe diffuse thickening of the left caudal thoracic air sac due to aspergillosis infection in a golden eagle – marked with purple arrows.**

#### **Aspergillosis treatment:**

All cases of aspergillosis will require medical management with antifungal drugs. In most clinical studies the antiviral drug voriconazole appears to have greatest efficacy leading to improved treatment success. In addition, nebulisation therapy with antifungal drugs such as terbinafine and F10 disinfectant are required in some cases. Treatment courses of 8 weeks or more are commonly required – with blood tests and repeat endoscopic exams being utilised to monitor treatment success.

If singular/focal lesions are identified these are sometimes amenable to surgical removal. This is particularly the case with syrinx granulomas or single air sac lesions.

#### **Aspergillosis prevention:**

Even with appropriate treatment some cases of aspergillosis infection are fatal or result in permanent damage to the respiratory system and a loss of flying performance. Minimizing the exposure to excessive spores and preventing unnecessary stressors help reduce the risk of aspergillosis in falconry birds. Prophylactic treatment can be used in specific circumstances (ie with high risk birds undergoing veterinary treatment) but excessive use of prophylaxis risks aspergillus becoming resistant to treatment. It also needs to be considered that a number of the treatments can cause side-effects – particularly to the liver and should not be used unnecessarily.