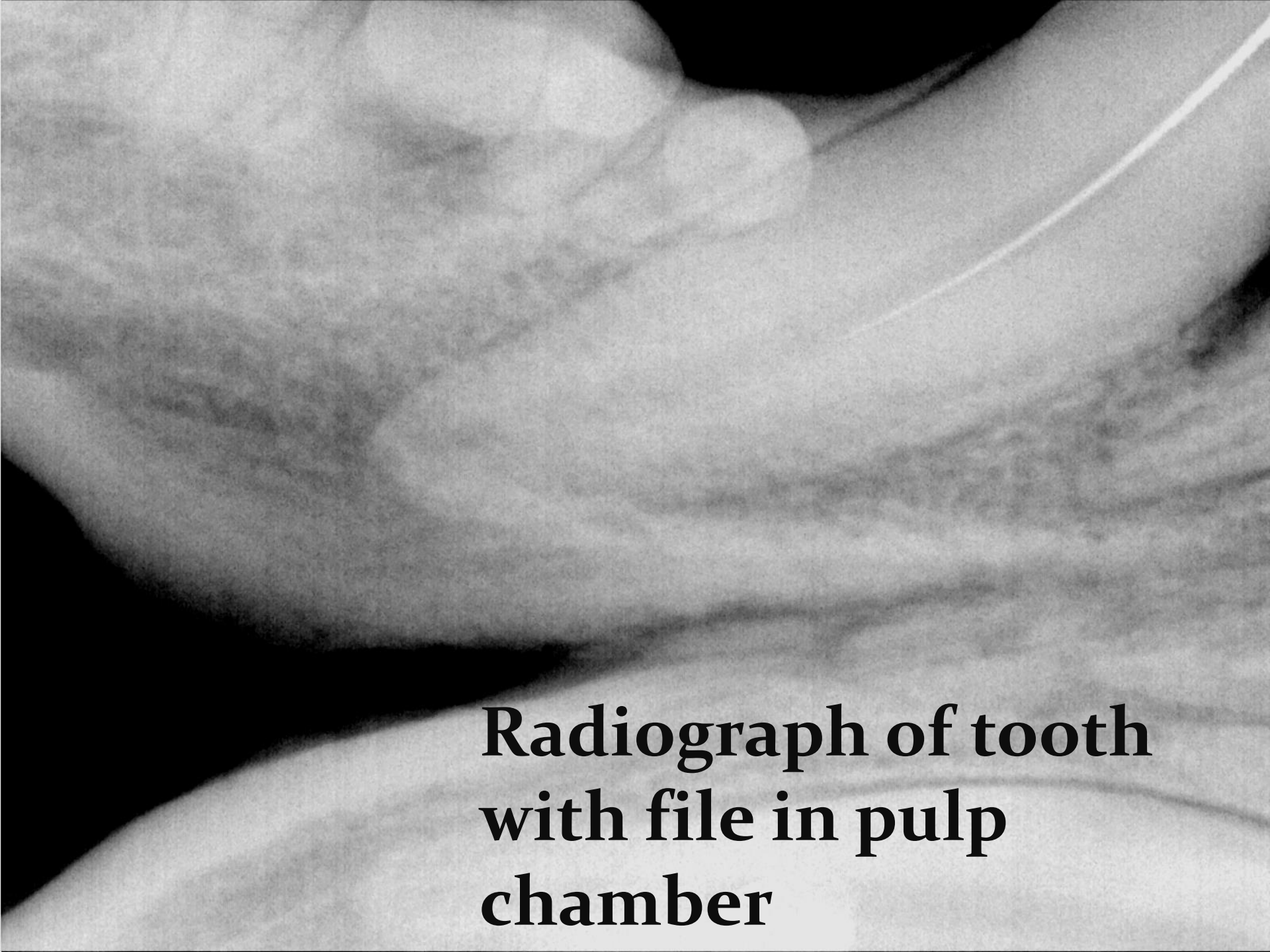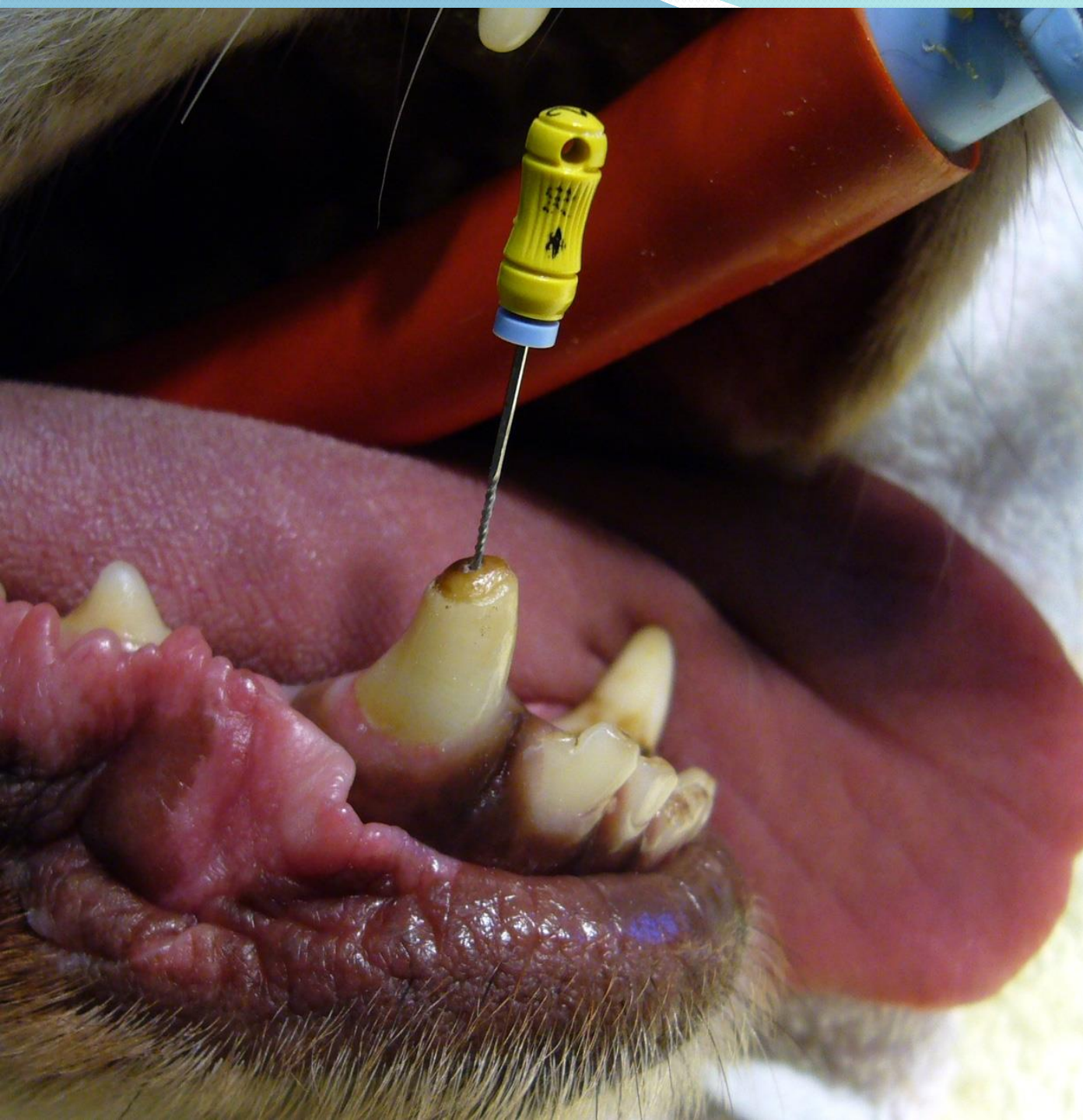


**Fractured Canine Tooth**

**Root Canal Therapy**



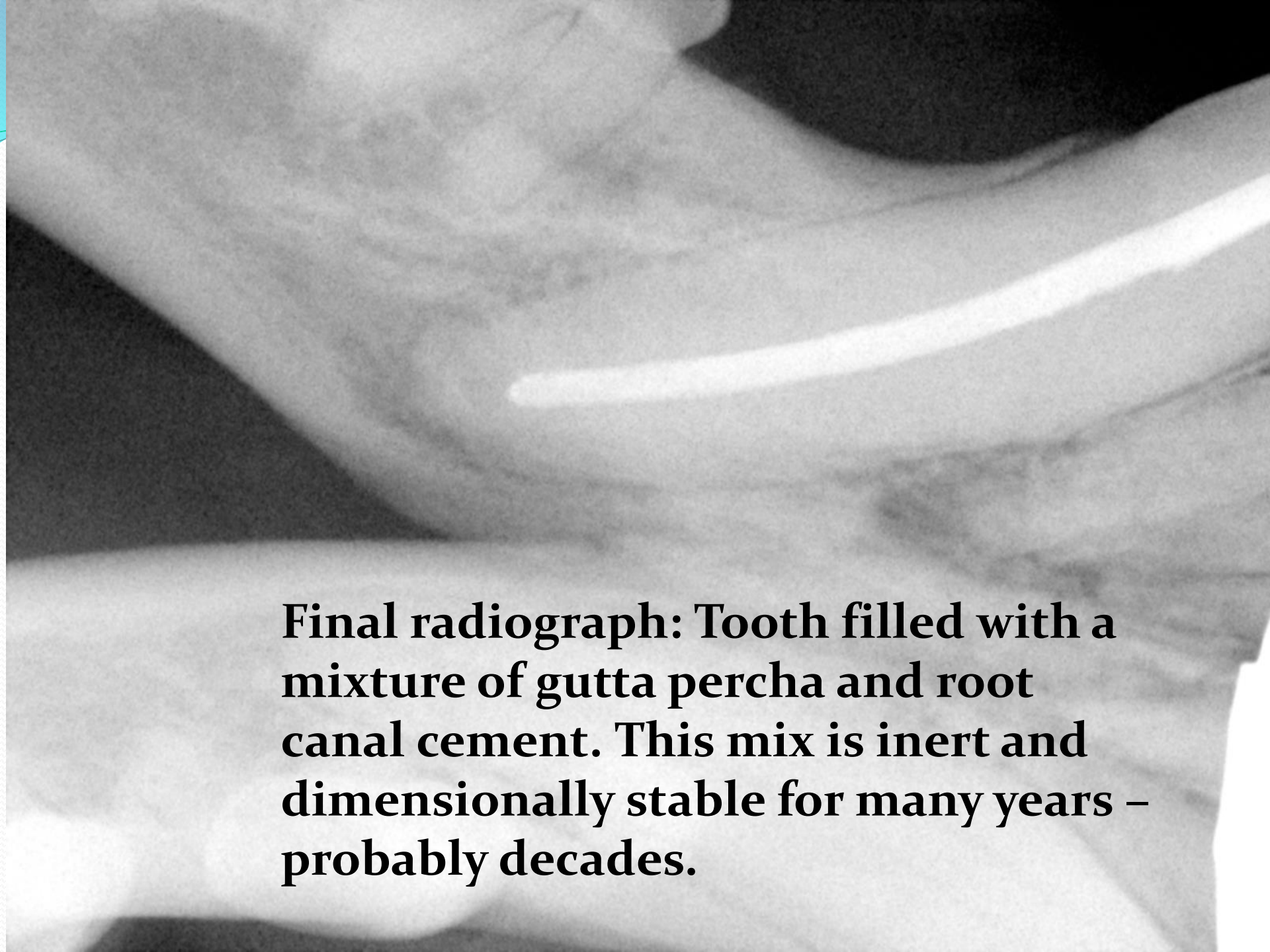
**Fractured  
right lower  
canine  
with  
file in  
open pulp  
access**

A black and white radiograph of a tooth. The image shows the internal pulp chamber and root canal. A thin, dark line representing a file is visible within the pulp chamber. The surrounding bone and soft tissue are shown in various shades of gray.

**Radiograph of tooth  
with file in pulp  
chamber**

A close-up, grayscale photograph of a dental root canal. A white, cylindrical file is inserted into the canal, extending to the bottom. The canal walls are visible, showing some texture and a slight curve. The background is dark, making the white file and canal stand out.

**Largest file to reach  
the full working  
length of root canal**



**Final radiograph: Tooth filled with a mixture of gutta percha and root canal cement. This mix is inert and dimensionally stable for many years – probably decades.**